

Pathology of Pre-Cancer and Invasive Cancer of the Uterine Cervix: An Overview

Dr. D.P.SINGH
Department of
RADIOTHERAPY
M.G.H JAIPUR

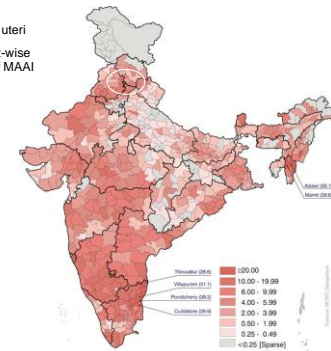


Cervical Cancer- Facts

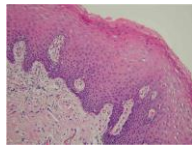
- Second most common cancer in women worldwide
- The most common / 2nd most common cancer affecting Indian women with an MAAI around 25 per 100,000 women
- The global incidence is 5,00,000 per year of which India contributes approx 1/4th. Around 1,25,000 new cases are diagnosed in India each year.
- By current trends, in the next quarter of a century, 5 million Indian women could be diagnosed with cervical cancer and 2.5 million of them may die of it!



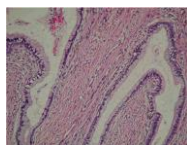
Cervix uteri
District-wise
map of MAAI



Cervix – Normal histology



Exocervix
Stratified Squamous
epithelium

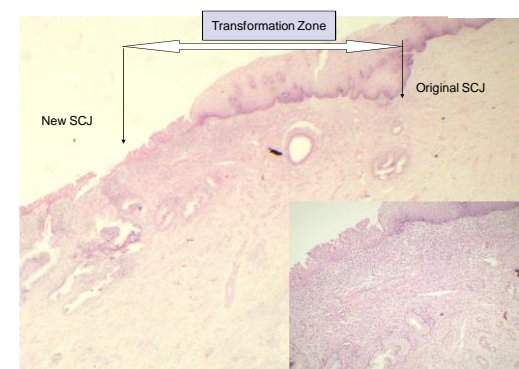


Endocervix
Columnar mucin-producing
epithelium epithelium



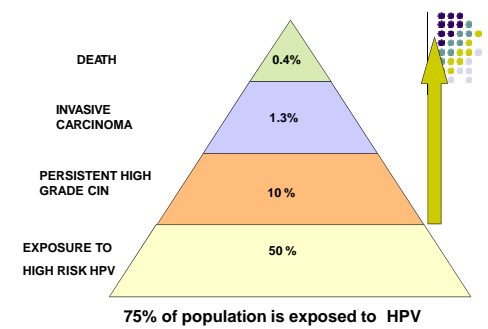
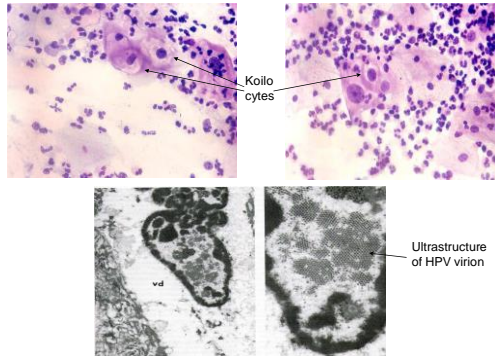
Squamocolumnar Junction and Transformation Zone

- SCJ is defined as the border between the stratified squamous epithelium and the mucin-secreting endocervical epithelium
- Morphogenetically, there are two SCJ.
 - **Original SCJ** - seen at birth.
 - Subsequently, with puberty, sexual activity and pregnancy there is 'ectopy' of the endocervical epithelium which undergoes squamous metaplasia resulting in the formation of
 - **'New SCJ'**
 - The region between the original and new SCJ is the **Transformation Zone or TZ.**
- This concept is extremely important for understanding the pathogenesis of cervical cancer because virtually all of these lesions originate here.

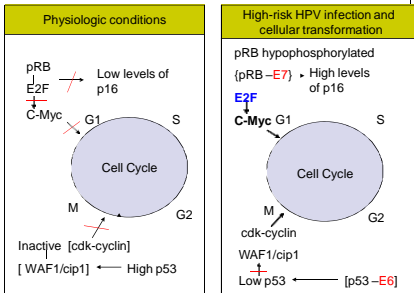


HPV & Cervical cancer

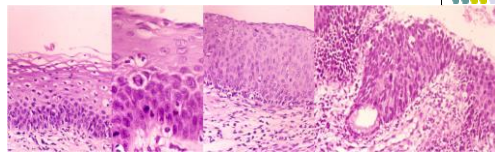
- Originally proposed by zur Hausen, it is now accepted that infection by Human Papilloma virus is critical for the causation of cervical cancer
- Strength and consistency of association** : HPV DNA is detected by hybridization techniques in >95 % of cancers.
- HPV divided based on oncogenic risk-
 Low risk: 6, 11, 42, 43, 44, 53
 High risk: 16, 18, 45, 56, 58
 Other high risk: 31, 33, 35, 39, 51, 52, 59, 68



Pathogenesis of cervical cancer: Interaction of HPV proteins with the cell cycle



Natural History of Cervical Intraepithelial Neoplasia: Approximate rates of progression, persistence and regression



	Regress %	Persist %	Progress % to CIN3	Progress % to Inv Ca
CIN1	60	30	10	<1
CIN2	40	35	20	5
CIN3	30	48	n/a	22

Arends et al, J Clin pathol, 1998; Holowaty et al, J Natl Can Inst, 1999; McIndoe et al 1984; Melnikow et al, Obstet Gynecol, 1998.

Rationale for screening

- Development of cervical cancer proceeds in a predictable fashion over a long period, allowing ample opportunity for intervention at a pre-cancer stage.
- Primary goal of cervical cytological screening- to identify women, in whom further evaluation with colposcopy is required to detect the presence of true cancer precursors.
- Cancer cervix is preventable by early detection by primary prevention (Etiology), secondary prevention (Pap smear) and tertiary prevention (Down Staging the disease).

Cervical cancer screening

- VIA/ VILI (Visual Inspection after application of Acetic Acid/ Lugol's iodine)- Fewer False Negatives
- Pap Smear– Fewer False Positives
- HPV Testing
 - Women who persistently test negative for HPV, very rarely develop cervical neoplasia
 - Therefore, the suggestion to use HPV testing as the primary screening device
 - Prohibitory Cost



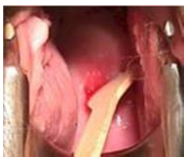The Pap Smear

- **George Papanicolaou** discovered that tumor cells could be found in vaginal fluid of women with cervical cancer – a seminal discovery!
- The developed world has witnessed a 75% reduction in the incidence of, and a 70% reduction in the mortality from invasive cancer due to the Pap test
- **Screening can be population based or hospital based**
- Countries with **“Once in a lifetime Pap Smear”- 40% reduction**
- **Indian Scenario- Disappointing**
 - Scattered projects undertaking a population-based screening
 - Several Hospital-based screening centers

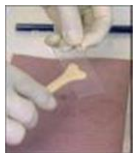
How to Perform a Pap Test

- **The patient should not be actively menstruating. It is preferable that the patient refrain from sexual activity or use of vaginal medications or spermicides for the 48 hours prior to the test. Cervical irritation can lead to obscuring inflammation or reactive changes on the smear.**
- **Insert appropriately sized bivalve speculum. Do not use lubricant jelly. Instead, use water for easier passage of the speculum.**
- **If mucus or small amounts of blood are on the cervix, gently remove with a large cotton swab with a dabbing motion (to avoid removing cells from the transformation zone).**

How to Perform a Pap Test



- Scrape cervix with the Ayre's Spatula by inserting the larger irregularly shaped side of the spatula into the endocervix and turning 360 degrees, making sure to cover the entire transformation zone. [Endocervical brush and broom smears are optional]



- Spread the cells from the spatula onto a numbered slide, evenly, avoiding clumping. Immediately fix the smear in a coplin jar containing 95% alcohol (alternatively use spray fixative at a distance of 12 inches, to avoid disrupting the cells)

CERVICAL PAP SMEAR REQUEST FORM NEW / FOLLOW-UP

- SLIDE NO: _____ NEW / FOLLOW UP
- NAME _____
- AGE _____
- I.D. NO. _____
- ADDRESS: _____
- CHIEF COMPLAINTS: Discharge / spotting / post-coital bleeding / menorrhagia / others _____
- CONTRACEPTION: Barrier / Hormonal / IUCD / Tubal ligation / Others _____
- H/O ANY THERAPY: None / Surgery / Radiotherapy / Chemotherapy _____
- PER SPECULUM FINDINGS: cervix normal / erosion / bleeds on touch / Suspicious _____
- COLPOSCOPIC FINDINGS: Not Done / Unsatisfactory / Normal / Not Done _____

Recommendations for Screening

Whom to Test ?

- All women who are sexually active, starting within three years after onset of sexual activity
- All women over 21 years of age
- In a Low-resource setting, even a once-in-a-lifetime screen of a woman between 35-60 years of age will provide protection against cervical cancer (WHO)

Frequency of screening

- Dependent on resources available
- Once-in-a-lifetime for low-resource countries
- Otherwise, once in 3– 5 years is recommended
- In case of smear reported as a low grade epithelial abnormality, it is repeated after 6 months

Potential reduction in cumulative cervical cancer rates with different frequencies of screening

Frequency of screening	Percent reduction in cumulative rate
Every year	90-95%
Every 2 years	86-91%
Every 3 years	75-88%
5 times per life time	61-74%
3 times per life time	35-55%
2 times per life time	29-42%
1 time per life time	17-32%

The Bethesda System 2001

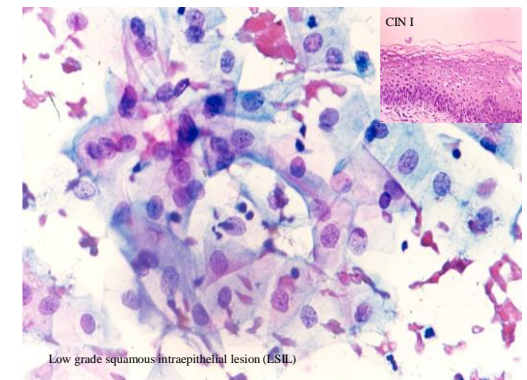
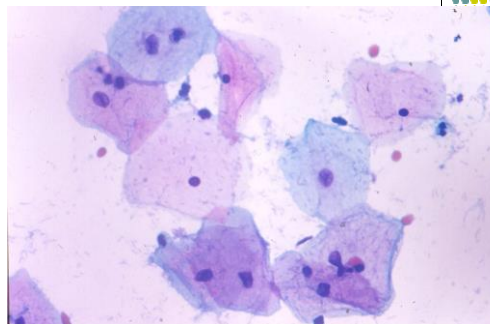
INTERPRETATION / RESULT

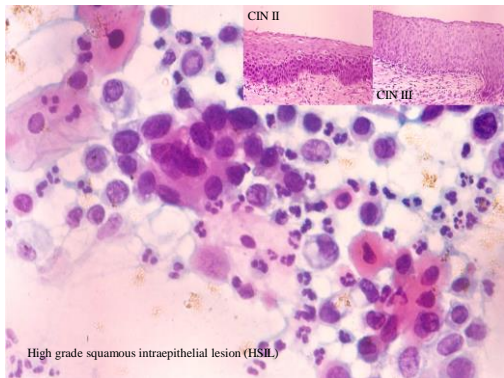
- **NEGATIVE** for Intraepithelial lesion or malignancy
- Other non neoplastic findings
- Reactive cellular changes associated with: Inflammation (includes typical repair) **Organisms:**
 - Trichomonas vaginalis
 - Fungal: Candida
 - Altered flora: Actinomyces species
 - Herpes Simplex virus
- Radiation
 - Intrauterine Contraceptive Devices(IUD)
 - Glandular cells status post hysterectomy
 - Atrophy
 - Other: Endometrial cells (in a woman \geq 40 years of age) (Specify if 'negative for squamous intraepithelial lesion')

The Bethesda System 2001

- **Epithelial Cell Abnormalities**
- **Squamous cells**
 - Atypical squamous cells
 - Undetermined significance (ASC- US)
 - Can not exclude H SIL (ASC- H)
 - **Low grade Squamous Intraepithelial Lesion (LSIL)** encompassing: HPV/mild dysplasia/CIN 1
 - **High grade Squamous Intraepithelial Lesion (HSIL)** Encompassing: moderate and severe dysplasia, CIS; CIN 2 and CIN 3
- **Squamous Cell Carcinoma**
 - With features suspicious for Invasion (if invasion is suspected)

Normal smear





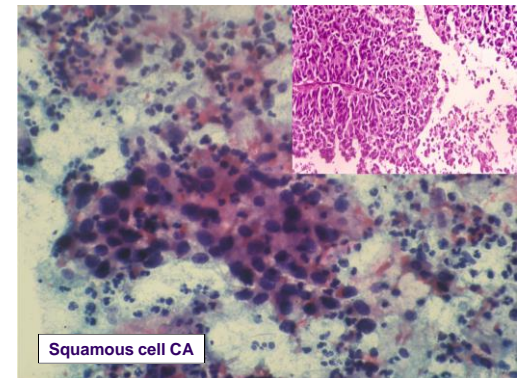
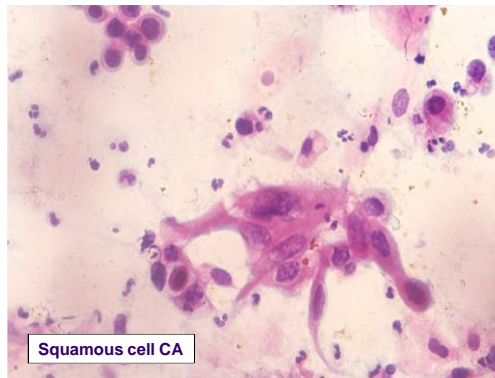
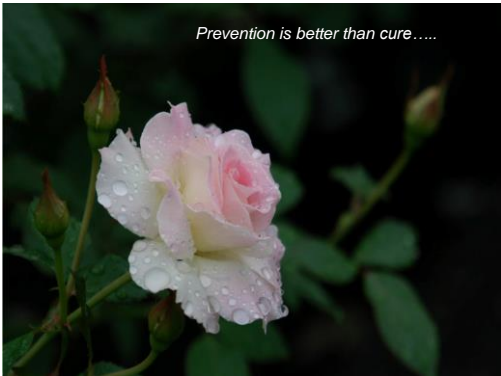Pap test as a guide to management of cervical Pre-cancer

Cervical smear results	Significance/Meaning	Actions
LSIL (2% of Pap tests)	Mild cell changes 85% will regress spontaneously over 2 years; about 15% will worsen. 0.1% will become invasive if left ignored	Need colposcopy or biopsy. Treatment may be necessary.
HSIL (0.5% of Pap tests)	Moderate or severe cell changes. 1-2% chance of becoming invasive cancer if untreated	Need colposcopy or biopsy. Treatment is necessary
Invasive	Cells with features suggestive of invasive cervical cancer	Urgent referral to gynecologist for investigation and treatment

PAP smear

- Although cervical smear is currently the most effective way to prevent cervical cancer, no test is perfect.
- False negative: (about 5-20% of cervical smears), due to sampling, transfer or laboratory error.
- False positive: due to over interpretation of changes of repair, inflammation, radiation, degeneration & florid squamous metaplasia
- Liquid-based Pap test: improves both sensitivity and specificity

Prevention is better than cure.....



Invasive Carcinoma of the uterine cervix



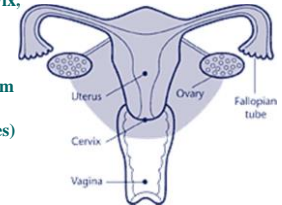
FIGO Staging of Cervical Cancer

Stage	Definition
0	Carcinoma in situ (preinvasive carcinoma)
I	Cervical carcinoma confined to uterus (extension to the corpus should be disregarded)
IA	Invasive carcinoma diagnosed only by microscopy; all macroscopically visible lesions, even with superficial invasion, are stage IB
IA1	Stromal invasion no greater than 3.0 mm in depth and 7.0 mm or less in horizontal spread
IA2	Stromal invasion > 3.0 mm and not more than 5.0 mm with a horizontal spread of 7.0 mm or less
IB	Clinically visible lesion confined to the cervix or microscopic lesion greater than IA2
IB1	Clinically visible lesion 4.0cm or less in greatest dimension
IB2	Clinically visible lesion more than 4.0 cm in greatest dimension
II	Tumor invades beyond the uterus but not to pelvic wall or to lower third of the vagina
IIA	Without parametrial invasion
IIB	With parametrial invasion
III	Tumor extends to the pelvic wall and/or involves lower third of vagina and/or causes hydronephrosis or nonfunctioning kidney
IIIA	Tumor involves lower third of vagina with no extension to pelvic wall
IIIB	Tumor extends to pelvic wall and/ or causes hydronephrosis or nonfunctioning kidney
IVA	Tumor invades mucosa of bladder or rectum and/or beyond true pelvis*
IV	Distant metastasis

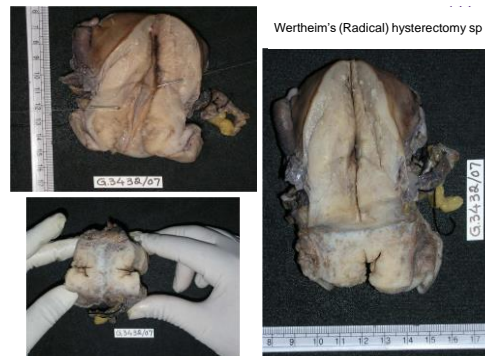
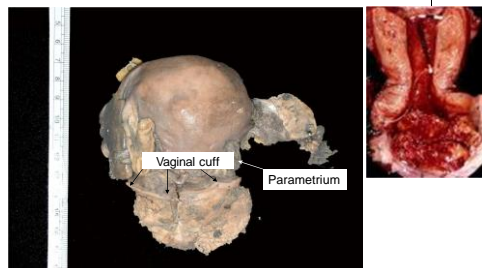


Wertheim's hysterectomy (Radical hysterectomy)

- Body of uterus and cervix, upper portion of the vagina (vaginal cuff), fallopian tubes, usually the ovaries, parametrium (the broad ligament below the fallopian tubes) and lymph glands and fatty tissue in the pelvis removed.



Wertheim's hysterectomy



Wertheim's (Radical) hysterectomy sp

Gross features

- **Specimen type:** Hysterectomy/ Radical hysterectomy- Wertheim's
- **Tumor site:** Right superior quadrant/ Rt inf quadrant/ Lt sup quad/ Lt inf quadrant/ Not specified
- **Tumor size:**
- **Extent of tumor** [stromal invasion /upward extension]
- Uterine corpus/ Vaginal cuff/ Parametrium



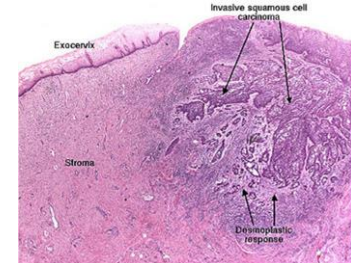
WHO Histological Classification of Invasive carcinomas of uterine cervix

- Squamous Cell CA
 - Microinvasive
 - Invasive
 - Well differentiated (large cell keratinising)
 - Moderately differentiated (large cell nonkeratinising)
 - Poorly differentiated (small cell type)
 - Verrucous
 - Warty (condylomatous)
 - Papillary (transitional)
 - Lymphoepithelioma like
- Adenocarcinoma
 - Mucinous
 - Endocervical
 - Intestinal
 - Signet-ring type
 - Endometrioid
 - Clear cell ca
 - Minimal deviation adenoCa
 - Villoglandular
 - Serous
 - Mesonephric

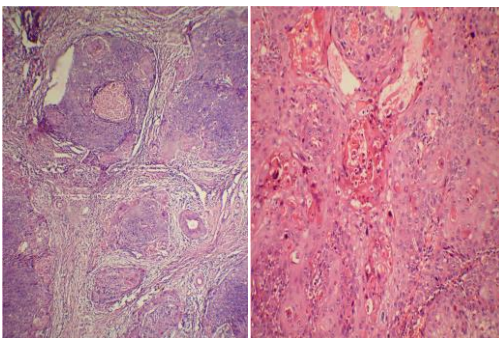
Carcinoma cervix – histopathological types

- Others
 - Adenosquamous ca
 - Glassy cell ca
 - Adenoid cystic
 - Undifferentiated ca
 - Small cell ca
 - Carcinoid
 - Large cell neuroendocrine ca

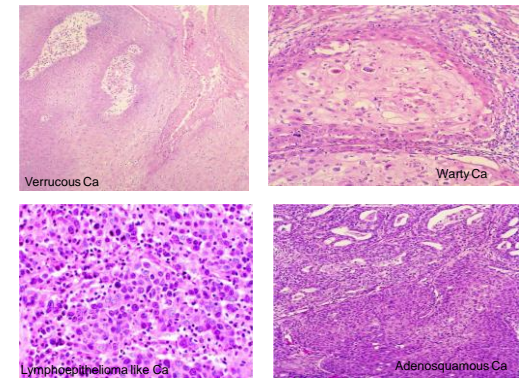
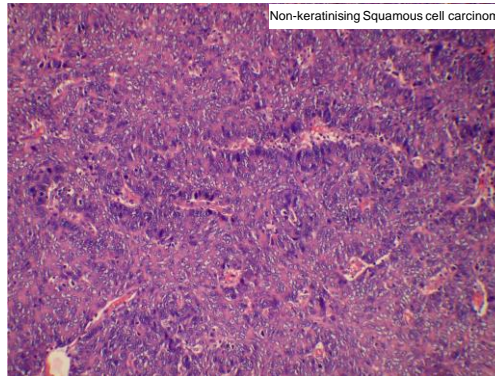
Early invasive squamous cell carcinoma

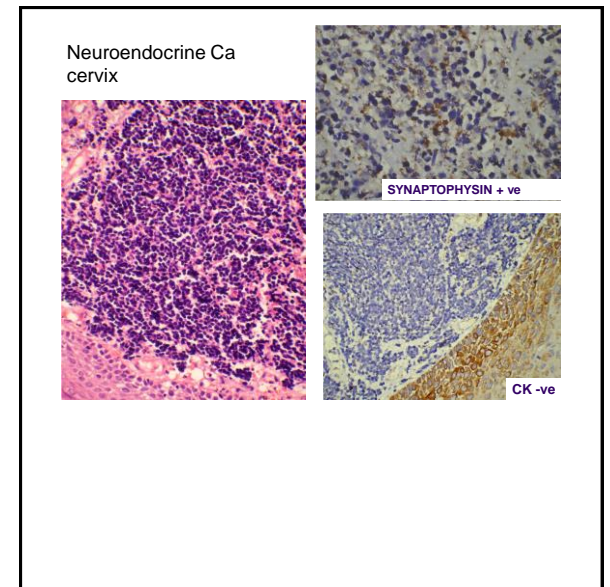
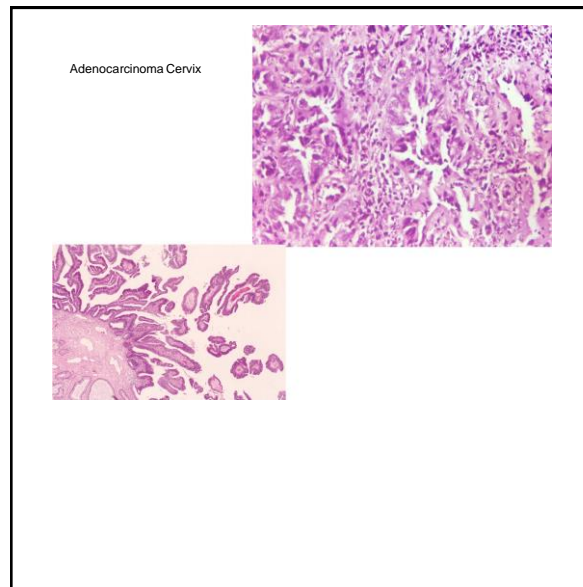
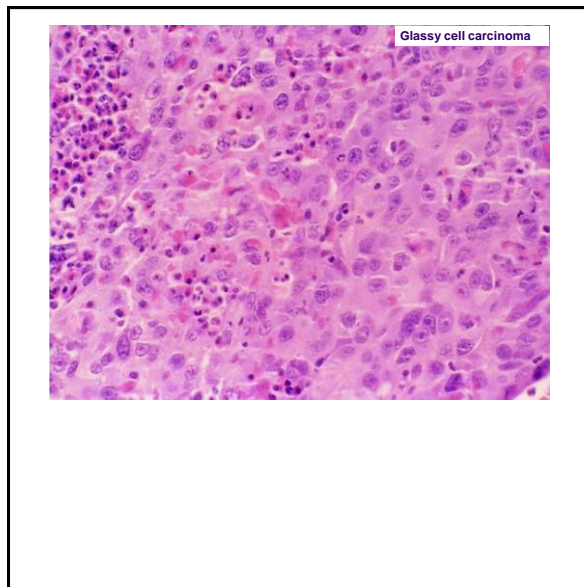


Keratinizing SCC



Non-keratinising Squamous cell carcinoma





Histological type and prognosis

- For a given stage, the histological type of tumor has little bearing on the prognosis.
- However, some subtypes such as small cell carcinoma, neuroendocrine carcinoma and adenosquamous ca tend to have a worse prognosis

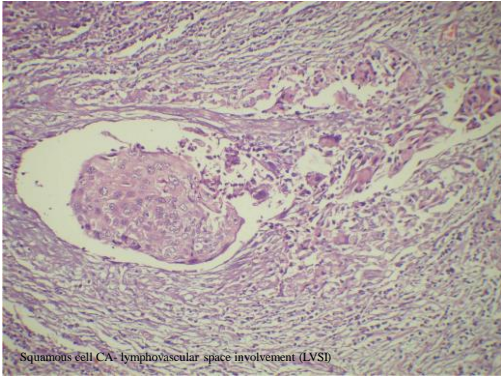
Histopathologic Prognostic factors

- Tumor size
- Depth of invasion (measured in millimeters or in thirds of cervical stromal thickness)
- Tumor growth pattern
- Mitotic rate
- Lympho-vascular space involvement (LVS)
- Status of the surgical margins
- Vaginal involvement
- Lymph node status
- Parametrial involvement.

Depth of cervical stromal invasion

- Increasing depth of invasion strongly correlate pelvic nodal spread and diminished progressive-free interval (PFI) at 5 years. Cancer 1992; 69: 1750-8
- Increasing depth of invasion correlates closely with parametrial extension. Cancer 1984; 54:3035-42.

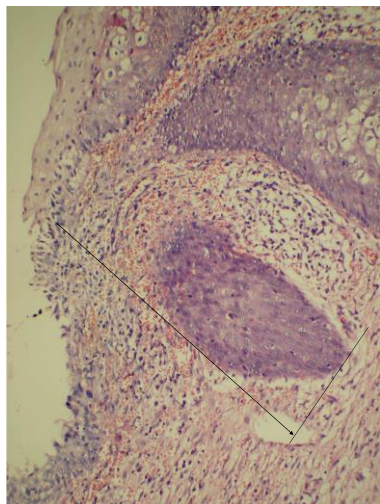
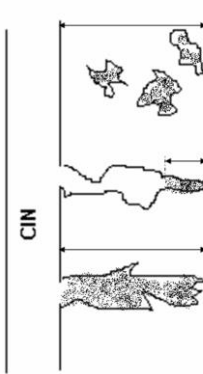
Depth of invasion	% positive nodes	% PFI at 5 yr
3-4 mm	0	100
5-7 mm	18	88
8-10 mm	23	77
11-15 mm	32	54
16+ mm	23	54



Microinvasive Squamous Cell carcinoma (FIGO Stage IA)

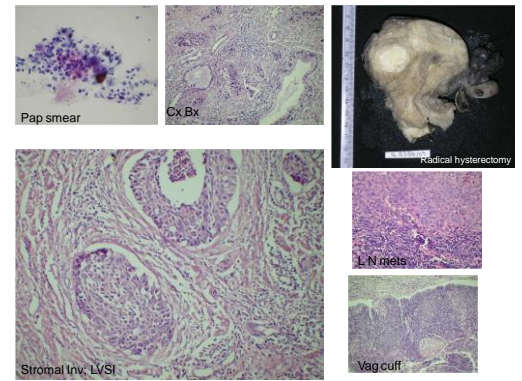
- Also known as Superficially Invasive carcinoma or carcinoma with early invasion. Tongues of malignant cells penetrate the basement membrane
 - IA- Depth of invasion is not more than 5mm from the base of the epithelium and horizontal spread not more than 7mm
 - IA1 – stromal invasion \leq 3mm
 - IA2 – stromal invasion $>$ 3mm
- Diagnosis by pap smear is difficult and done by biopsy – a cone biopsy or LEEP specimen
MICA have virtually no potential for metastases or recurrence

DEPTH OF INVASION




Canned report

Specimen type: Hysterectomy/ Radical hysterectomy- Wertheim's
Tumor site: Right superior quadrant/ Rt inf quadrant/ Lt sup quad/ Lt inf quadrant/ Not specified
Tumor size:
Extent of tumor [stromal invasion /upward extension]
 Uterine corpus/ Vaginal cuff/ Parametrium
Other organs:
 Rt. Ovary/ Lt. Ovary/ Rt. Fallopian tube/ Lt. Fallopian Tube
Microscopy:
 Histologic Type:
 Histologic Grade:
 Extent of invasion:
Margins (check all that apply):
 Cannot be assessed/ Uninvolved by ca/ Distance of tumor from closest margin/ Specify if in-situ changes are present at distal margin
 Margin Involved –Specify location
Lymphatic and venous invasion: Present / Absent / indeterminate
Additional pathological findings: None / intraepithelial neoplasia / others
Comment:
Pathologist:



Sample HPE Report

- **Specimen type:** Radical hysterectomy- Wertheim's
- **Tumor site:** Circumferential
- **Tumor size:** 4X3X2 cms
- **Extent of tumor** [stromal invasion /upward extension]
 - Uterine corpus – Free
 - Vaginal cuff – involved
 - Parametrium- Free
- **Other organs:** Rt. Ovary/ Lt. Ovary/ Rt. Fallopian tube/ Lt. Fallopian Tube - Free
- **Microscopy:**
 - Histologic Type: Squamous cell Ca, non-keratinising
 - Histologic Grade:G2
 - Extent of invasion:More than half stromal thickness
- **Margins** (check all that apply):
 - Distance of tumor from closest margin – 3mm, involved
- **Lymphatic and venous invasion:** Present
- **Lymph nodes:** Ext iliac group : Metastases present (1/3), Rest - free
- **Pathologist:**



Treatment of Cervical Cancer

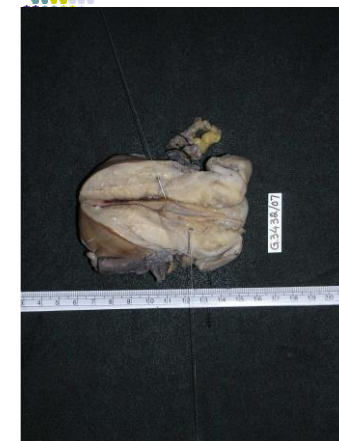- ❖ **Stage 0:** Loop electrosurgical excision procedure (LEEP), laser therapy, conization or cryotherapy
- ❖ **Stage IA:** Standard treatment- **total hysterectomy.**
 - Lymph node dissection is not required if the **depth of invasion is less than 3 mm and no lympho-vascular invasion** is noted.
- ❖ **Stage IB or IIA**
 - Either **combined external beam radiation with brachytherapy or radical hysterectomy** with bilateral pelvic lymphadenectomy.

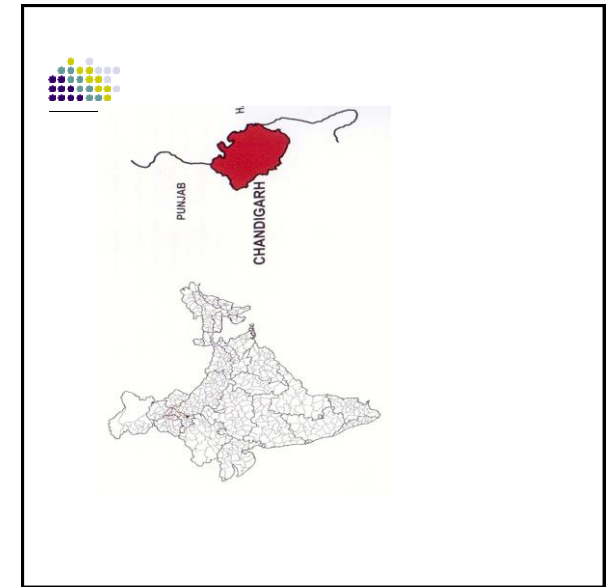


Treatment of Cervical Cancer

- ❖ **Stage IIB, III and IVA**
 - **Radiation therapy-** the treatment of choice
 - For locally advanced cervical cancer- use of cisplatin-based chemotherapy in combination with radiation.
- ❖ **Stage IVB and recurrent cancer**
 - **Chemotherapy-** single agent cisplatin or combined use of cisplatin and topotecan
 - **Palliative radiation/ Total pelvic exenteration** may be considered.

Prognosis of cervical cancer

- Stage I cancer is confined to the cervix and has a 5-year-survival of 80-90%.
- Stage II cancer extends beyond the cervix and has a 5-year-survival of 50-65%.
- Stage III cancer extends to the pelvic wall and has a 5-year-survival of 25-35%.
- Stage IV cancer extends beyond the pelvic area and has a 5-year-survival of 0-15%.





Pap Smear Reporting format

- SLIDE No. _____ I.D. No. _____ PAP SMEAR NO. _____
- SATISFACTORY FOR INTERPRETATION / UNSATISFACTORY (STATE REASON)
- **NO EVIDENCE OF EPITHELIAL ABNORMALITY**
- **EPITHELIAL ABNORMALITY PRESENT**
- **BENIGN CELLULAR CHANGES**
- **INFLAMMATORY**
- **ASC-US**
- **LSIL (WITH OR WITHOUT HPV ASSOCIATED CHANGES)**
- **HSIL**
- **SQUAMOUS CELL CARCINOMA - ? INVASIVE / INVASIVE**
- **GLANDULAR CELLS**
- Endometrial Cells, Cytologically Benign Post-Menopausal Woman
- AGUS
- **ADENOCARCINOMA: ENDOCERVICAL / ENDOMETRIAL / OTHERS**
- **CYTODIAGNOSIS**
- **RECOMMENDATION: TREAT AND REPEAT / FOLLOW-UP SMEAR AFTER 4-6 MONTHS / BIOPSY CONFIRMATION**
- DATE: _____ CYTOSCREENER
CYTOPATHOLOGIST

- **Solid nests of tumor cells with glassy, eosinophilic cytoplasm**
- **Large eosinophilic nuclei, prominent nucleoli**
- **Surrounded by heavy inflammatory infiltrate containing eosinophils;**
- **Frequent mitotic figures**
- **Pure cases have no histologic evidence of glandular or squamous differentiation, which is detectable only by EM**
- **Positive stains: PAS in cell wall**
- **EM: adenosquamous features**